

Cataract Case of the Month CME Series

EYE ON CATARACT™

CHALLENGING CASES MADE ROUTINE

This Month's Case

Cataract Surgery in a Patient Who Is Post-Myopic LASIK

ORIGINAL RELEASE: DECEMBER 15, 2015 • **LAST REVIEW:** OCTOBER 26, 2015 • **EXPIRATION:** DECEMBER 31, 2016

Program Chair

John Sheppard, MD, MMSc

Professor of Ophthalmology
Eastern Virginia Medical School
President
Virginia Eye Consultants
Norfolk, Virginia

Faculty

Anthony J. Aldave, MD

Associate Professor of Ophthalmology
The Jules Stein Eye Institute
University of California, Los Angeles
Los Angeles, California

Deepinder K. Dhaliwal, MD

Associate Professor of Ophthalmology
Director, Cornea, Cataract, and External Disease Service
Director, Refractive and Laser Surgery Center
Director, UPMC Eye Center Monroeville
Director and Founder, Center of Integrative Eye Care
University of Pittsburgh School of Medicine
Pittsburgh, Pennsylvania

Bonnie An Henderson, MD

Clinical Professor of Ophthalmology
Tufts University School of Medicine
Ophthalmic Consultants of Boston
Boston, Massachusetts

Jay S. Pepose, MD, PhD

Professor of Clinical Ophthalmology
Barnes-Jewish Hospital
Washington University School of Medicine
Medical Director
Pepose Vision Institute
St. Louis, Missouri

William B. Trattler, MD

Volunteer Assistant Professor of Ophthalmology
Bascom Palmer Eye Institute
University of Miami
Director of Cornea
Center for Excellence in Eye Care
Miami, Florida

CME Reviewer for New York Eye and Ear Infirmary of Mount Sinai

Joseph F. Panarelli, MD

Assistant Professor of Ophthalmology
Associate Residency Program Director
New York Eye and Ear Infirmary of Mount Sinai
New York, New York

LEARNING METHOD AND MEDIUM

This educational activity consists of a case discussion and study questions. The participant should, in order, read the learning objectives at the beginning of this case discussion, read the case discussion, answer all questions in the post test, and complete the Activity Evaluation/Credit Request form. To receive credit for this activity, please visit <http://www.tinyurl.com/EyeOnCataract-2> and follow the instructions provided on the post test and Activity Evaluation/Credit Request form. This educational activity should take a maximum of 0.75 hour to complete.

CONTENT SOURCE

This continuing medical education (CME) activity captures content from an expert roundtable discussion held in San Diego, California, on April 16, 2015.

ACTIVITY DESCRIPTION

Cataract surgery is the most commonly performed surgery among adults in the United States, and the number of patients undergoing this procedure is continuing to increase. For patients who are identified as candidates for cataract surgery, optimization of the ocular surface is critical for obtaining optimal patient outcomes. There are a host of new tools that can help cataract surgeons with their preoperative evaluations. Among these are several tests that are useful adjuncts for diagnosing dry eye/meibomian gland dysfunction. The purpose of this activity is to update ophthalmologists on recent advances in the care of patients with cataracts.

TARGET AUDIENCE

This activity is intended for ophthalmologists.

LEARNING OBJECTIVES

Upon completion of this activity, participants will be better able to:

- Manage preoperative ocular surface conditions with potential to affect surgical outcomes in patients with cataracts
- Demonstrate optimal IOL selection, knowledge of appropriate refractive targets, and understanding of strategies for achieving intended goals
- Discuss risks and benefits of cataract surgery with patients
- Describe the benefits of new diagnostic technologies with application to cataract surgery

ACCREDITATION STATEMENT

This activity has been planned and implemented in accordance with the accreditation requirements and policies of the Accreditation Council for Continuing Medical Education (ACCME) through the joint providership of New York Eye and Ear Infirmary of Mount Sinai and MedEdicus LLC. The New York Eye and Ear Infirmary of Mount Sinai is accredited by the ACCME to provide continuing medical education for physicians.

In July 2013, the Accreditation Council for Continuing Medical Education (ACCME) awarded New York Eye and Ear Infirmary of Mount Sinai "Accreditation with Commendation," for six years as a provider of continuing medical education for physicians, the highest accreditation status awarded by the ACCME.

AMA CREDIT DESIGNATION STATEMENT

The New York Eye and Ear Infirmary of Mount Sinai designates this enduring material for a maximum of 0.75 AMA PRA Category 1 Credit™. Physicians should claim only the credit commensurate with the extent of their participation in the activity.

GRANTOR STATEMENT

This continuing medical education activity is supported through an unrestricted educational grant from Bausch + Lomb Incorporated.

DISCLOSURE POLICY STATEMENT

It is the policy of New York Eye and Ear Infirmary of Mount Sinai that the faculty and anyone in a position to control activity content disclose any real or apparent conflicts of interest relating to the topics of this educational activity, and also disclose discussions of unlabeled/unapproved uses of drugs or devices during their presentation(s). New York Eye and Ear Infirmary of Mount Sinai has established policies in place that will identify and resolve all conflicts of interest prior to this educational activity. Full disclosure of faculty/planners and their commercial relationships, if any, follows.

DISCLOSURES

Faculty had financial agreements or affiliations during the past year with commercial interests as follows:

Dr Aldave: Consultant/Advisory Board: Allergan; Nicox; and TearScience; Honoraria from promotional, advertising or non-CME services received directly from commercial interests or their Agents (eg, Speakers Bureaus): Alcon; and Allergan; Other/Travel Support: Laboratoires Théa; and Tissue Banks International. **Dr Dhaliwal:** Consultant/Advisory Board: AMO Lasers; and NovaBay Pharmaceuticals; Research Grants: Abbott Medical Optics; Avedro; and Eleven Biotherapeutics. **Dr Henderson:** Consultant/Advisory Board: Abbott Medical Optics; Alcon; and Bausch + Lomb. **Dr Pepose:** Consultant/Advisory Board: Abbott Medical Optics; Alcon; Allergan; Bausch + Lomb; Shire; and TearLab; Ownership Interest: Acufocus. **Dr Sheppard:** Consultant/Advisory Board: AbbVie; Alcon; Allergan; Bausch + Lomb;

Bio-Tissue; Omeros; TearLab; and TearScience; Honoraria from promotional, advertising or non-CME services received directly from commercial interests or their Agents (eg, Speakers Bureaus): Alcon; Bausch + Lomb; ScienceBased Health; and TearLab; Ownership Interest: Alphaeon; EyeGate Pharma; OcuHub; Rapid Pathogen Screening; TearLab; and 1-800-Doctors. **Dr Trattler:** Consultant/Advisory Board: Abbott Medical Optics; Alcon; Allergan; and Bausch + Lomb; Contracted Research: Refocus Group; Honoraria from promotional, advertising or non-CME services received directly from commercial interests or their Agents (eg, Speakers Bureaus): Allergan; and OCULUS, Inc; Ownership Interest: Calhoun Vision; CXL Ophthalmics; and Rapid Pathogen Screening.

NEW YORK EYE AND EAR INFIRMARY OF MOUNT SINAI PEER REVIEW DISCLOSURE

Joseph F. Panarelli, MD, has no relevant commercial relationships to disclose.

EDITORIAL SUPPORT DISCLOSURES

Cheryl Guttman (writer); Cynthia Tornallyay, RD, MBA, CHCP; Kimberly Corbin, CHCP; Barbara Aubei; Diane McArdle, PhD; and Barbara Lyon have no relevant commercial relationships to disclose.

DISCLOSURE ATTESTATION

The contributing individuals listed above have attested to the following: 1) that the relationships/affiliations noted will not bias or otherwise influence their involvement in this activity;

- 2) that practice recommendations given relevant to the companies to whom they have relationships/affiliations will be supported by the best available evidence or, absent evidence, will be consistent with generally accepted medical practice; and
- 3) that all reasonable clinical alternatives will be discussed when making practice recommendations.

OFF-LABEL DISCUSSION

This CME activity includes discussion of unlabeled and/or investigative uses of drugs. Please refer to the official prescribing information for each drug discussed in this activity for FDA-approved dosing, indications, and warnings.

FOR DIGITAL EDITIONS

System Requirements:

To view this online activity, please ensure the computer you are using meets the following requirements:

- **Operating System:** Windows or Macintosh
- **Media Viewing Requirements:** Flash Player or Adobe Reader
- **Supported Browsers:** Microsoft Internet Explorer, Firefox, Google Chrome, Safari, and Opera
- **A good Internet connection**

New York Eye and Ear Infirmary of Mount Sinai

Privacy & Confidentiality Policies

<http://www.nyee.edu/health-professionals/cme/enduring-activities>

CME Provider Contact Information

For questions about this activity, call 212-979-4383.

TO OBTAIN AMA PRA CATEGORY 1 CREDIT™ for this activity, read the material in its entirety and consult referenced sources as necessary. We offer instant certificate processing and support Green CME. Please take this post test and evaluation online by going to <http://www.tinyurl.com/EyeOnCataract-2>. Upon passing, you will receive your certificate immediately. You must score 70% or higher to receive credit for this activity, and may take the test up to 2 times. Upon registering and successfully completing the post test, your certificate will be made available online and you can print it or file it.

There are no fees for participating in and receiving CME credit for this activity.

DISCLAIMER

The views and opinions expressed in this educational activity are those of the faculty and do not necessarily represent the views of New York Eye and Ear Infirmary of Mount Sinai, MedEdicus LLC, Bausch + Lomb Incorporated, or *Ophthalmology Times*.

Jointly provided by New York Eye and Ear Infirmary of Mount Sinai and MedEdicus LLC



Cataract Surgery in a Patient Who Is Post-Myopic LASIK

John Sheppard, MD, MMSc; Anthony J. Aldave, MD; Deepinder K. Dhaliwal, MD; Bonnie An Henderson, MD; Jay S. Pepose, MD, PhD; William B. Trattler, MD

Case from the files of William B. Trattler, MD

A 67-year-old female with a history of myopic LASIK (laser-assisted in situ keratomileusis) performed 15 years earlier by another surgeon presents with a complaint of reduced vision. She reports being very satisfied with the outcome of her refractive surgery, but says her vision has been deteriorating over the last 2 or 3 years.

Slit-lamp examination shows bilateral cataract that is worse in the left eye (2+ NS). Left eye uncorrected visual acuity (UCVA) is 20/40, best corrected visual acuity (BCVA) is 20/30-2, and manifest refraction is plano +1.00 x 170.

The cornea is clear, but subtle flap striae are visible, and a few punctate epithelial erosions are seen inferiorly with fluorescein staining. Mild meibomian gland dysfunction (MGD) is diagnosed as well, and topography reveals irregular astigmatism (Figure 1). No retinal abnormalities are found on macular coherence tomography (OCT).

The patient is started on loteprednol gel twice daily and topical cyclosporine twice daily for her ocular surface disease (OSD), and returns after 2 weeks. Topography is repeated. Although a different type of system was used (Scheimpflug camera because the Placido disc platform used in the prior examination needed servicing), the imaging shows persistence of irregular astigmatism in the central cornea (Figure 2).

The patient is scheduled for cataract surgery, anticipating that she would derive some benefit in terms of improved BCVA. Preoperative counseling, however, included a discussion about the uncertainty of her vision outcome due to the inability to know exactly how much her vision was affected by her cornea irregularity.

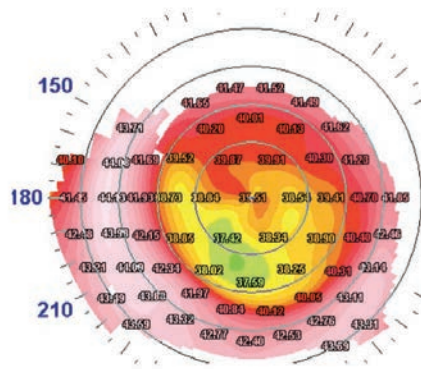


Figure 1. Preoperative topography of a 67-year-old female 15 years after myopic LASIK shows irregular astigmatism.

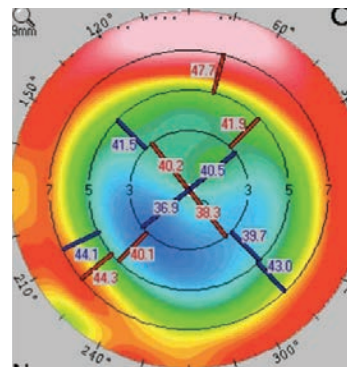


Figure 2. Topography showing irregular astigmatism at 2 weeks after initiating treatment for OSD.

Images Courtesy of William B. Trattler, MD

She undergoes uncomplicated cataract surgery with implantation of an aspheric monofocal intraocular lens (IOL) (Figure 3). At her 1-month visit, the patient is unhappy with her vision. On examination, UCVA is 20/50-, BCVA is 20/30, and MR is +1.50 +1.00 x 165. She has persistence of mild punctate epithelial erosions and 1+ posterior capsule opacification.

Treatment for OSD, which included another pulse of loteprednol gel twice daily for 3 weeks and topical cyclosporine, was resumed, and Nd:YAG laser capsulotomy was performed. One month

later, the patient remains unhappy and describes her vision as worse than before cataract surgery; UCVA is 20/50. She says she now needs glasses for distance, and she reports poorer quality of vision.

PREOPERATIVE EXAMINATION

Ocular surface disease is a common finding in the cataract surgery population and needs to be addressed preoperatively because it affects the accuracy of the keratometry measurements used for IOL calculation as well as the quality of vision after surgery.

In addition to the findings from a careful clinical examination for dry eye, which would include lid evaluation and expression, fluorescein and lissamine green staining, and tear film break-up time, the findings of irregular astigmatism on topography and drop-out of the mires on Placido disc topography are clues to the presence of dry eye disease. The follow-up topography that was performed preoperatively in this patient was done with the Scheimpflug imaging system that enables detection of irregular astigmatism due to a misshaped cornea, but it does not pick up irregularities from OSD. Therefore, it was assumed that her persistent irregular astigmatism was due to the flap striae and corneal remodeling over time, but not to a suboptimal ocular surface, therefore justifying the decision to proceed with surgery. The flap-related irregular astigmatism also explains why she did not have a better postoperative visual outcome. Over-refraction with a rigid gas permeable (RGP) contact lens may have been helpful preoperatively to assess how the corneal irregularity was affecting her vision and how much improvement might be expected after cataract surgery.

A comprehensive preoperative examination should also include assessment for posterior segment pathology. As a minimum standard of care, patients should undergo a dilated fundus examination. However, macular OCT can help with detection of subtle pathology [see Sidebar: Macular OCT Prior to Cataract Surgery].





Macular OCT Prior to Cataract Surgery

William B. Trattler, MD

Identification of preexisting retinal pathology is essential when undertaking cataract surgery because it influences visual potential, quality of vision, and risk for postoperative cystoid macular edema (CME). Macular OCT is a valuable aid for retina evaluation, considering that visualization of the posterior segment may be limited when looking through the cataract.

The potential for overlooking existing pathology using direct examination alone in eyes of cataract surgery patients was demonstrated in a study comparing findings of preoperative and postoperative retinal photographs.¹ The investigators identified epiretinal membrane in 3.1% of eyes before surgery and in 14.8% at 1 month after the procedure; there was low agreement between the findings of the 2 diagnostic examinations.

Anecdotally, I have been impressed by my experience using preoperative OCT that has allowed me to identify unsuspected retinal pathology.

Therefore, I routinely perform macular OCT preoperatively in all cataract surgery patients. Because this is a screening procedure, it is not billable to insurance, and the imaging is done without charging the patient. If any pathology is identified, charges for subsequent OCT examination can be submitted for insurance reimbursement.

1. Fong CS, Mitchell P, Rochtchina E, Hong T, de Loryn T, Wang JJ. Incidence and progression of epiretinal membranes in eyes after cataract surgery. *Am J Ophthalmol.* 2013;156(2):312-318.

A

AL: 25.41mm (SNR = 509.4) K1: 38.70 D / 8.72mm @ 36° K2: 39.38 D / 8.57mm @ 126° R/SE: 8.64mm / 39.04 D Cyl: 0.68 D @ 126° ACD: 3.59mm Status: Phakic								OS left	
Tecnis MF1 ONE ZMB00		TORIC-SN6AT		Tecnis Multifocal ZMB00 1pc		Tecnis Multifocal ZMA00 3pc			
A const: 119.30		A const: 119.10		A0 const: 1.508 A1 const: 0.400 A2 const: 0.100		A0 const: 1.375 A1 const: 0.400 A2 const: 0.100			
IOL (D)	REF (D)	IOL (D)	REF (D)	IOL (D)	REF (D)	IOL (D)	REF (D)		
23.5	-2.16	23.0	-1.96	26.0	-2.21	25.5	-2.03		
23.0	-1.78	22.5	-1.57	25.5	-1.82	25.0	-1.65		
22.5	-1.40	22.0	-1.20	25.0	-1.44	24.5	-1.27		
22.0	-1.03	21.5	-0.82	24.5	-1.07	24.0	-0.90		
21.5	-0.66	21.0	-0.46	24.0	-0.70	23.5	-0.52		
21.0	-0.30	20.5	-0.09	23.5	-0.34	23.0	-0.16		
20.5	0.06	20.0	0.27	23.0	0.02	22.5	0.20		
Emme. IOL: 20.59		Emme. IOL: 20.37		Emme. IOL: 23.03		Emme. IOL: 22.78			

Figure 3. IOL power selection planning. [A] Note that the Tecnis monofocal ZCB00 and the Tecnis multifocal ZMB00 have the same A-constant: 119.3. [B] The Haigis-L for myopia suggests the 23.5 D 1-piece aspheric hydrophobic acrylic IOL will result in a postoperative refractive error of -0.34 D. The ASCRS (American Society of Cataract and Refractive Surgery) Post Keratorefractive On-Line Calculator supports using this IOL power.

B

IOL Calculator for Eyes with Prior Myopic LASIK/PRK
(Your data will not be saved. Please print a copy for your records.)

Please enter all data available and press "Calculate"

Doctor Name	William Trattler	Patient Name	Post-LASIK Left Eye	Eye	OS	IOL Model	ZCB00	Target Ref (D)	-0.50
*Adjusted Atlas 9000 (4mm zone)		-		*Shammas		24.14 D			
*Adjusted Atlas Ring Values		-		*Haigis-L		23.73 D			
Masked Formula		-		*Galilei		-			
Modified-Masket		-		*Potvin-Hill Pentacam		-			
*Adjusted ACCP/ACP/APP		-		*OCT		-			
Barrett True K		-		*Barrett True K No History		23.43 D			

PREOPERATIVE OSD MANAGEMENT

Treatment for OSD is guided by the underlying cause and the desired timing for resolution. This patient presented with MGD, which is the most common cause of evaporative dry eye disease.¹ Treatment for patients with minimal to mild MGD includes lid hygiene, topical azithromycin, artificial lubricants, and consideration of an oral tetracycline.² Anti-inflammatory treatment may be indicated for managing dry eye in patients with moderate MGD.²

The conventional lid hygiene method consists of application of warm compresses with lid massage. Historically, a mild baby shampoo has been suggested as a cleanser; however, there is a lack of quality evidence to support use of baby shampoo. In theory, it may be detrimental because its detergent action can cause further breakdown of the already compromised lipid layer.

A number of products have been developed specifically as lid cleansers for patients with MGD. They vary in price, ingredients, and, anecdotally, in their likelihood to cause stinging. Although there also is a lack of evidence demonstrating that these products are superior to warm compresses with lid massage, they may be associated with higher patient acceptance on the basis of such factors as convenience of use and pleasing aesthetics. As a result, patients may be more likely to comply with their lid cleansing regimen, which would translate into better efficacy. With compliance in mind and knowing

that simplicity of the regimen is important, it is reasonable to instruct patients to perform lid hygiene once or twice a day. Devices designed for in-office use to treat MGD by relieving gland obstruction are also available (<http://tinyurl.com/EyeOnCataract-1PDF>). [See Cataract Case of the Month, "A Patient With Mixed Aqueous Deficiency/Evaporative Dry Eye Disease" in the September issue of *Ophthalmology Times*.] These treatments are not covered by insurance, and so out-of-pocket cost may be an issue limiting their use.

When patients require ocular surface optimization and are eager to have surgery as soon as possible, treatment with a topical corticosteroid combined with punctal plugs will allow for more rapid control of inflammation. If long-term anti-inflammatory control is anticipated—and surgery can be delayed for several months so that an immediate "fix" is not needed—topical cyclosporine can be initiated along with preservative-free artificial tears. With this regimen, punctal plug placement should be withheld for 4 to 6 weeks so that the ocular surface is not exposed to a tear film full of inflammatory mediators. Initiating a topical corticosteroid prior to or concomitantly with the topical cyclosporine would hasten resolution of the inflammation, allow earlier placement of the punctal plugs, mitigate cyclosporine-induced burning and stinging, and provide faster improvement of dry eye-related symptoms.^{3,4}

IOL DECISIONS IN THE POST-LASIK PATIENT

Power calculation. Accurate IOL power calculation is challenging in the post-LASIK eye because the laser ablation affects corneal power. Multiple methods have been introduced to better determine the true corneal power after LASIK, and numerous formulas have been suggested for calculating IOL power in these cases. None of the approaches is perfect, although some formulas seem to perform better than others in patients who have had myopic refractive surgery.^{5,6}

Individual surgeons may have a preference for a particular formula or, if not, they can use various online systems, such as the postrefractive IOL calculator (iolcalc.org) or the Hoffer/Savini LASIK IOL Power Tool (<https://www.iolpowerclub.org/post-surgical-iol-calc>) in which IOL power calculations are performed using all available data and multiple formulas. Intraoperative aberrometry offers another option for refining IOL power selection in these challenging postrefractive surgery cases, and 2 groups have reported positive results.^{5,7} Ultimately, however, the surgeon needs to apply clinical judgment, given that the programs generally suggest a range of powers.

Spherical aberration. IOL asphericity is another issue to consider in the postkeratorefractive surgery eye. In general, an IOL with negative spherical aberration is preferred in a post-myopic LASIK eye because the surgery likely induced some positive spherical aberration. In contrast, a spherical IOL or one with zero spherical aberration would be appropriate for a posthyperopic LASIK eye that likely has negative spherical aberration. An argument can also be made to favor an IOL with zero spherical aberration in all postkeratorefractive surgery patients according to the reasoning that image quality with that optic design is less sensitive to decentration and tilt. Its use may minimize the potential for disabling coma-related vision problems. A decentered aspheric IOL can, however, induce coma that can be associated with persistent ghosting.⁹ Even though a conventional IOL that has positive spherical aberration reduces contrast sensitivity, consequences of its use may be modest in older patients because these individuals have smaller pupils.

The choice between an aspheric, aberration-neutral and a spherical IOL can be individualized by measuring the actual amount of corneal spherical aberration. This information is directly

available on some topographers or aberrometers. It is available directly on some topography systems and on some combined topography/aberrometry systems.

Presbyopic correction. Postrefractive surgery patients, in particular, might desire reduced spectacle dependence after cataract surgery and be interested in a presbyopia-correcting IOL. Surgeons should, however, proceed cautiously with implanting a multifocal IOL in any patient who has had a higher level of myopic correction (≥ -6 to -7 D) because it is likely to have introduced some multifocality of the cornea that would limit good-quality vision. An accommodating IOL with zero spherical aberration might be a better choice for these patients.

REFLECTIONS ON THE CASE

With her history of keratorefractive surgery and the presence of both irregular corneal astigmatism and OSD, this patient presented several challenges for achieving a good visual outcome after cataract surgery. Her case illustrates the importance of a comprehensive preoperative examination: to identify issues that can compromise the accuracy of the surgical result and postoperative quality of vision, to promote aggressive management of any treatable conditions, and to allow for a thorough informed consent discussion to set appropriate expectations.

Perhaps this patient may have had a better outcome if she had been implanted with a zero spherical aberration IOL, but she likely still would have had significant complaints because such a lens would not have addressed her uncorrected irregular astigmatism, which appears to be the main cause for her less-than-satisfactory outcome.

A wavefront analysis might be performed to evaluate the potential influence of higher-order aberrations on the quality of vision. Because pupil diameter influences ocular higher-order aberrations,⁹ topical 1% pilocarpine or 0.2% brimonidine might be tried in this patient to see if pupil constriction improves her vision.

An RGP lens can also be offered noting that a larger scleral RGP lens is a more comfortable option than a traditional RGP lens. Even if patients with irregular astigmatism decline RGP wear, a trial in the office demonstrating they have potential for good vision may have psychological value for these individuals and further establish that their decreased vision is due to preexisting cornea irregularity and is not a complication of the cataract surgery.

SUMMARY

Various strategies exist to improve refractive accuracy and maximize postoperative vision in patients with a history of keratorefractive surgery. Even under the best of circumstances, however, cataract surgeons face challenges in delivering optimal outcomes. Extensive patient counseling is needed in these cases, and surgeons should carefully document all the information in both the chart and the written informed consent.

REFERENCES

- Nichols KK, Foulks GN, Bron AJ, et al. The International Workshop on Meibomian Gland Dysfunction: Executive Summary. *Invest Ophthalmol Vis Sci.* 2011;52(4):1922-1929.
- Geerling G, Tauber J, Baudouin C, et al. The International Workshop on Meibomian Gland Dysfunction: Report of the Subcommittee on Management and Treatment of Meibomian Gland Dysfunction. *Invest Ophthalmol Vis Sci.* 2011; 52(4):2050-2064.
- Byun YJ, Kim TI, Kwon SM, et al. Efficacy of combined 0.05% cyclosporine and 1% methylprednisolone treatment for chronic dry eye. *Cornea.* 2012;31(5): 509-513.
- Sheppard JD, Donnenfeld ED, Holland EJ, et al. Effect of loteprednol etabonate 0.5% on initiation of dry eye treatment with topical cyclosporine 0.05%. *Eye Contact Lens.* 2014;40(5):289-296.
- Fram NR, Masket S, Wang L. Comparison of intraoperative aberrometry, OCT-based IOL formula, Haigis-L, and Masket formulae for IOL power calculation after laser vision correction. *Ophthalmology.* 2015;122(6):1096-1101.
- McCarthy M, Gavanski GM, Paton KE, Holland SP. Intraocular lens power calculations after myopic laser refractive surgery: a comparison of methods in 173 eyes. *Ophthalmology.* 2011;118(5):940-944.
- Ianchulev T, Hoffer KJ, Yoo SH, et al. Intraoperative refractive biometry for predicting intraocular lens power calculation after prior myopic refractive surgery. *Ophthalmology.* 2014;121(1):56-60.
- Altmann GE, Nichamin LD, Lane SS, Pepose JS. Optical performance of 3 intraocular lens designs in the presence of decentration. *J Cataract Refract Surg.* 2005;31(3):574-585.
- Oshika T, Tokunaga T, Samejima T, Miyata K, Kawana K, Kaji Y. Influence of pupil diameter on the relation between ocular higher-order aberration and contrast sensitivity after laser in situ keratomileusis. *Invest Ophthalmol Vis Sci.* 2006;47(4):1334-1338.

