

Choroidal Melanoma

Standards, Innovations and Future Directions

What you need to know!

The methods for diagnosis and treatment of choroidal melanoma have changed. Herein, these changes are described along with why they are important to you or your patients.

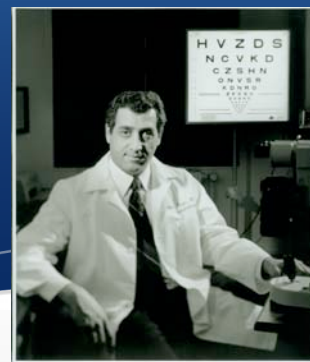
Page 3

Choroidal melanoma is the most common primary intraocular cancer in adults.

Dr. Finger rarely needs to biopsy a choroidal melanoma to make the diagnosis. While some centers are using biopsy to determine the genetic make-up of each tumor, this information not certain enough to change our methods of treatment. Since there is risk involved with placing a needle or biopsy instrument into the eye, Dr. Finger will only biopsy when the clinical diagnosis is uncertain, when a patient requires a diagnosis by pathology or when the intraocular tumor is a metastasis from a hidden "occult" primary. In over 99% of cases, the diagnosis can be made by clinical examination.

In addition, Dr. Finger has spent the last 30-years working to improve treatments for choroidal melanoma. His special training in ophthalmic radiation therapy, has allowed him to developed new and improved methods to treat tumors (including those previously considered untreatable) in other centers.

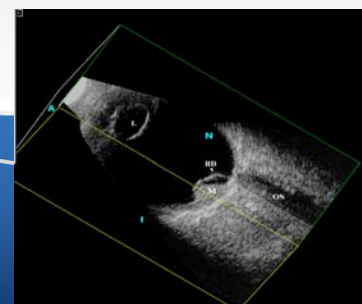
Continued on Page 4



Intraocular Tumors

- Vascular** Most vascular tumors can be watched or treated with laser or cryotherapy.
- Nevi** These tumors are common and should be differentiated from melanoma.
- Melanoma** Both vision and life threatening, these tumors should be treated.
- Metastasis** Most patients will present with a history of systemic metastases.
- Others** Many different tumors occur in the eye and can be differentiated by eye cancer specialists.

Dr. Finger typically uses ultrasound imaging (2D and 3D) used to monitor for initial tumor size or growth, make sure the plaque is in position during treatment and for regression after ophthalmic radiation therapy.



Palladium-103 Plaque Radiation Therapy

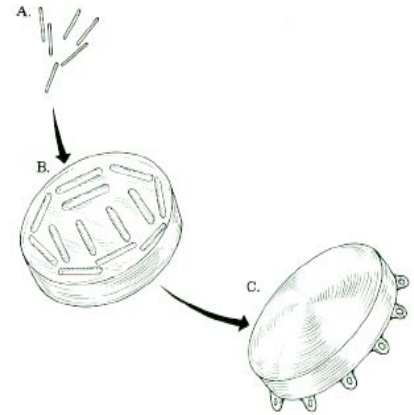
Eighteen years after he introduced palladium-103 eye plaque therapy, Finger and coworkers reported on their last 400 cases of uveal melanoma treated with palladium-103 ophthalmic plaque radiation therapy and compared them to series of similar size and follow up.

Table 2. Summary table of ¹⁰³Pd versus reported results using other forms of radiation therapy for uveal melanoma.

Authors	Radiation	Mean Dose (Gy)	Mean follow-up (months)	Recurrence (%)	Secondary Enucleation (%)	Neovascular Glaucoma (%)	Metastasis (%)	Visual Acuity
COMS ²⁰⁻²⁴	I-125	= or >85 Gy	60	10	13	N/A	10 (5year) 18 (10year)	57% > 20/200 at 3 years
Packer ²⁵	I-125	91	64	7.8	17.2	10.9	15.6	45% better or 20/100 at 5.3 years
Fontanesi ²⁶	I-125	79	46	2.3	9.7	5.5	5.5	41% better or 20/200 at 3.9 years
Lommatzsch ²¹	Ru-106	100	80	15	26	1.3	20	N/A
Char ²²	Helium	70	110	5	22	35	18.6 (5year) 23.6 (10year)	33% better or 20/200 at 10 years
Brovkina ²³	Proton	100-125	34	19	25	N/A	6	N/A
Gragoudas ²⁴	Proton	70	64	3	6	N/A	20.5	42% better than 20/200 at 5.3 years
Mean		87	65	9	17	11.7	13.7	variable
<i>Present study</i> Finger et al	Pd-103	73	51	3%	3%	2.5%	6%	79% better or 20/200 at 5 years 69% better or 20/200 at 10 years

Gy=Gray, COMS=Collaborative Ocular Melanoma Study, N/A=data not available, I-125=Iodine-125, Ru-106 = Ruthenium-106

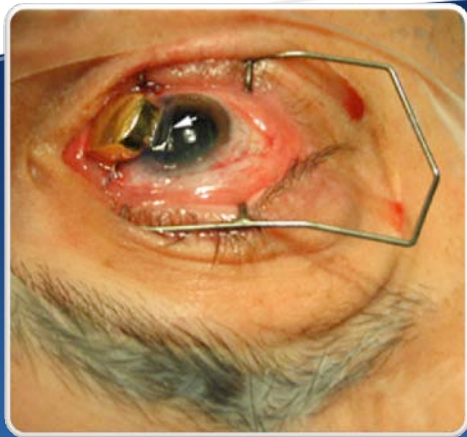
Dr. Finger’s similarly recruited consecutive case series resulted in a top **97% local control rate, less metastatic death and significantly better vision retention** than these reported series.



Eye Plaque Components

Radioactive ophthalmic plaques are custom-made by affixing radionuclide “seeds” into a gold shell (plaque).

- A. Radioactive seeds
- B. Seed carrier
- C. Gold plaque



This is an image of a Finger-designed gold eye plaque surgically attached to the eye wall above a malignant melanoma of the iris and ciliary body prior to closure (being covered with a Gunderson flap for comfort).

Anterior Eye Plaque Irradiation

This photograph demonstrates how an eye plaque can be placed onto the cornea as to treat a portion of the iris. Based on high-frequency ultrasound imaging (UBM) we calculate how deep the radiation needs to penetrate in order to destroy the underlying malignancy.

Dr. Finger originally described this technique in 2001. At that time he had followed patients for almost 10 years with more than 90% keeping within 2 lines of their original vision and no significant corneal damage.

He now has 20 years of experience with this technique and has found it to be a both a safe and effective method to destroy iris and iridociliary melanomas.

Plaque Radiation Therapy for Malignant Melanoma of the Iris and Ciliary Body. **Finger PT** *The American Journal of Ophthalmology* 2001;132:328-335.

Posterior Eye Plaque Irradiation: “Finger’s Slotted Plaque”

Proper plaque placement requires that the tumor’s base be covered along with a 2-3 mm margin of normal appearing tissue.

In treatment of melanomas near or surrounding the optic disc, the orbital portion of the optic nerve can obstruct proper plaque placement.

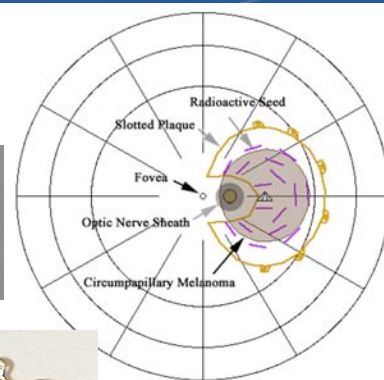

Radioactive eye-plaques are typically positioned on the sclera as to cover the intraocular tumor base plus a 2-3 mm free-margin of normal appearing tissue that is not possible in treatment of tumors that touch or surround the optic disk.

This is because the optic nerve exits the posterior aspect of the globe, creating an obstacle to proper plaque placement. In addition, the retrobulbar optic nerve sheath diameter is typically three times that of the optic disk diameter.

Therefore, even if a notched plaque is perfectly placed against the optic nerve sheath, the plaque’s posterior edge is likely to be at least 1.7-mm anterior to the optic disk or juxtapapillary tumor interface. Despite this anatomic handicap, plaque radiation therapy has offered local control of selected juxtapapillary tumors where plaque-notching, radiation side-scatter and posterior “plaque-tilting” have been suggested as factors that allow successful treatment.

This is why most eye cancer specialists will recommend enucleation or external beam irradiation for choroidal melanomas in contact with 180-degrees or more of the optic disk.

Finger’s “slotted” plaque design reduces the probability of geographic miss by allowing the entire optic nerve (plus a 2-mm free margin of safety) to be incorporated beneath the plaque. Further slotted plaques are ideally suited for low energy I-125 and Pd-103 plaque techniques. This is because the radioactive components of these plaques (rice-sized seeds) offer strengths and locations that can be



“Only Finger’s Slotted Plaque Technique allows complete coverage of the targeted zone (tumor base and 2-3 mm margin).”

modulated, conforming to the location and size of the tumor, plaque and slot. In contrast, to Ru-106 plaques are not designed to irradiate within the minimum 8-mm wide slot and have sharp penumbras that prevent the side-scatter needed to fill in the slot’s volume. Further, cutting into a Ru-106 plaque would create a serious radiation-safety hazard.

In comparison to external beam (e.g. radiosurgery, the gamma knife and proton-beam), slotted plaques offer the most conformal tumor treatment (much less irradiation of normal anterior ocular and adnexal structures).

In Dr. Finger’s reported series, pre-operative dosimetry studies demonstrate that juxtapapillary and circumpapillary choroidal melanomas received an adequate radiation dose. Thus, slotted plaques may be considered a safer alternative to notched plaques, an alternative to external beam irradiation and an eye and vision-sparing alternative to enucleation for choroidal melanomas that touch or surround the optic disk.

Side Effects / Complications

Radiation Optic Neuropathy and Maculopathy

Finger’s “Slotted” Eye Plaque For Radiation Therapy: Treatment of Juxtapapillary and Circumpapillary Intraocular Tumors

Finger PT

The British Journal of Ophthalmology 2007;91:891-94.

Continued from page 1

This includes the use of new isotopes (radionuclides) that offer the same or more radiation to the tumor, while relatively sparing most normal ocular structures. Dr. Finger knows that the key to vision is in limiting irradiation of the normal parts of the eye.

Dr. Finger’s has been invited by both The American Brachytherapy Society (ABS) and the American Association for Physics in Medicine (AAPM) to help them form recommendations for plaque therapy for intraocular tumors.

Unlike many centers, Dr. Finger requires that the radiation sources in his plaques (iodine-125 or palladium-103) be picked based on pre-treatment dose comparisons. Each patient’s plaque is custom-made for that patient. Every effort is made to make sure the tumor is destroyed and the patient has his or her best chance for vision.

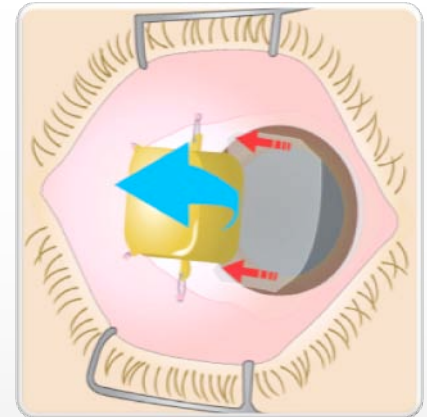
Though choroidal melanoma is the most common cancer to arise in the adult eye; it is very rare. Thought to occur in 4-6 people per million per year in the United States, it is found in 10 per million in Australia. More common in people with outdoor occupations, those with blue irises and fair skin, it is reasonable to assume that ultraviolet radiation from the sun plays a role. Dr. Finger says, “think of sunglasses as sun block for your eyes.”™

In 2009, Dr. Finger published a review of his last 400 cases of palladium-103 ophthalmic plaque radiation therapy in the scientific journal, OPHTHALMOLOGY. It was important to notice that he found a local control rate (rate of killing the tumor in the eye) of 96.7% and that 79% of patients’ retained useful vision. This track record was better than most all published series.

Palladium-103 Ophthalmic Plaque Radiation Therapy for Choroidal Melanoma: 400 Treated Patients.

Finger PT, Chin KJ, Duvall G et al. Ophthalmology 2009;116:790-6.

Notes:



About Patient Comfort: “Finger’s Amniotic Membrane Buffer Technique”

In 1991, Dr. Finger published his findings on radioactive eye plaque therapy for iris and iridociliary melanomas. With up to 10 years follow up, he found that the this treatment offered excellent local control with preservation of the iris and long-term clarity of the irradiated cornea.

In contrast to surgical removal, plaque therapy was done on the outside of the eye, did not risk intraocular hemorrhage or infection and preserved the normal iris function. Unlike intraocular surgical resection, larger margins could be treated.

Unfortunately, having a gold-metal plaque sewn to the cornea for 5-7 days was very uncomfortable.

This is why Dr. Finger immediately recognized that sliding a paper-thin piece of donor amniotic membrane between the plaque and the cornea would improve patient comfort. In addition, since this is human tissue, it does not affect the radiation therapy.

Finger’s Amniotic Membrane Buffer Technique.

Finger PT Arch Ophthalmol 2008;126(4):531-4.

About Paul T. Finger, MD

In his efforts to save life, conserve eyes and vision; Dr. Finger has pioneered the use of palladium-103 plaque radiation for choroidal melanoma and the use of 3D and high-frequency ultrasound imaging for intraocular tumors. He has created the world-renowned web sites: <http://eyecancer.com> and <http://paultfingermd.com>

Dr. Finger has developed new methods for the diagnosis and treatment of many ocular tumors, holds several patents and has written hundreds of scientific publications. Dr. Finger lectures frequently at local, national and international meetings.

Dr. Finger is certified by The American Board of Ophthalmology, a Fellow of the American College of Surgeons, Senior Fellow of the American Academy of Ophthalmology and cares for patients from all over the world.

Dr. Finger has a particular interest in choroidal melanoma, ciliary body melanoma and iris melanoma. He has written extensively about new ways to detect and treat conjunctival melanoma, squamous carcinoma, metastatic cancer to the eye and orbital tumors.



Dr. Finger is a Clinical Professor of Ophthalmology at New York University School of Medicine and Director of Ocular Tumor Services at The New York Eye Cancer Center, The New York Eye and Ear Infirmary, Manhattan Eye, Ear and Throat Hospital and NYU-Affiliated Hospitals

The New York Eye Cancer Center

115 East 61st Street – Suite 5B
New York, NY 10065

1212-832-8170 and <http://paultfingermd.com>

[Recipient]

Address Line 1

Address Line 2

Address Line 3

Address Line 4