



Visit <http://tinyurl.com/miosiscme> for online testing and instant CME certificate.

Case Discussions in Complicated Cataract



Miosis Control and Other Surgical Pearls

Proceedings From a CME Symposium During AAO 2015

Original Release: April 1, 2016 • Last Review: March 1, 2016 • Expiration: April 30, 2017

Faculty

Edward J. Holland, MD (Chair)

Eric D. Donnenfeld, MD

Bonnie An Henderson, MD

Terry Kim, MD

Jointly provided by **New York Eye and Ear Infirmary of Mount Sinai** and MedEdicus LLC



This continuing medical education activity is supported through an unrestricted educational grant from Omeros Corporation.

Distributed with EyeNet

Faculty

Edward J. Holland, MD (Chair)

Professor of Ophthalmology
The University of Cincinnati
Director, Cornea Services
Cincinnati Eye Institute
Cincinnati, Ohio

Eric D. Donnenfeld, MD

Clinical Professor of Ophthalmology
New York University
Langone Medical Center
New York, New York
Founding Partner
Ophthalmic Consultants of Long Island
Rockville Centre, New York

Bonnie An Henderson, MD

Clinical Professor of Ophthalmology
Tufts University School of Medicine
Ophthalmic Consultants of Boston
Boston, Massachusetts

Terry Kim, MD

Professor of Ophthalmology
Duke University School of Medicine
Chief, Cornea and External
Disease Division
Director, Refractive Surgery Service
Duke University Eye Center
Durham, North Carolina

CME Reviewer for New York Eye and Ear Infirmary of Mount Sinai

Priti Batta, MD

Assistant Professor of Ophthalmology
Icahn School of Medicine at Mount Sinai
Director, Medical Student Education
Assistant Director, Comprehensive
Ophthalmology Service
New York Eye and Ear Infirmary
of Mount Sinai
New York, New York

Learning Method and Medium

This educational activity consists of a supplement and ten (10) study questions. The participant should, in order, read the learning objectives contained at the beginning of this supplement, read the supplement, answer all questions in the post test, and complete the Activity Evaluation/Credit Request form. To receive credit for this activity, please follow the instructions provided on the post test and Activity Evaluation/Credit Request form. This educational activity should take a maximum of 1.5 hours to complete.

Content Source

This continuing medical education (CME) activity captures content from a CME symposium held on November 16, 2015, in Las Vegas, Nevada.

Activity Description

Preventing intraoperative miosis and controlling postoperative inflammation and pain are important for the success of cataract surgery and patient satisfaction. A variety of modalities can be used to achieve these goals, and the options have expanded with recent product introductions. The purpose of this activity is to update ophthalmologists on the available approaches and to present techniques for managing a few additional challenges of cataract surgery.

Target Audience

This activity is intended for ophthalmologists.

Learning Objectives

Upon completion of this activity, participants will be better able to:

- Identify optimal strategies for control of postoperative pain and inflammation for patients undergoing intraocular lens replacement
- Evaluate the benefits and risks of pharmacological agents for managing miosis
- Appraise the safety and efficacy of mechanical devices for managing miosis
- Incorporate evidence-based approaches for mydriasis maintenance in complicated cataract cases

Accreditation Statement

This activity has been planned and implemented in accordance with the accreditation requirements and policies of the Accreditation Council for Continuing Medical Education (ACCME) through the joint providership of **New York Eye and Ear Infirmary of Mount Sinai** and **MedEdicus LLC**. The **New York Eye and Ear Infirmary of Mount Sinai** is accredited by the ACCME to provide continuing medical education for physicians.



In July 2013, the Accreditation Council for Continuing Medical Education (ACCME) awarded New York Eye and Ear Infirmary of Mount Sinai "Accreditation with Commendation," for six years as a provider of continuing medical education for physicians, the highest accreditation status awarded by the ACCME.

AMA Credit Designation Statement

The **New York Eye and Ear Infirmary of Mount Sinai** designates this enduring material for a maximum of 1.5 **AMA PRA Category 1 Credits™**. Physicians should claim only the credit commensurate with the extent of their participation in the activity.

Grantor Statement

This continuing medical education activity is supported through an unrestricted educational grant from Omeros Corporation.

Disclosure Policy Statement

It is the policy of **New York Eye and Ear Infirmary of Mount Sinai** that the faculty and anyone in a position to control activity content disclose any real or apparent conflicts of interest relating to the topics of this educational activity, and also disclose discussions of unlabeled/unapproved uses of drugs

or devices during their presentation(s).

New York Eye and Ear Infirmary of Mount Sinai has established policies in place that will identify and resolve all conflicts of interest prior to this educational activity. Full disclosure of faculty/planners and their commercial relationships, if any, follows.

Disclosures

Eric D. Donnenfeld, MD, had a financial agreement or affiliation during the past year with the following commercial interests in the form of *Consultant/Advisory Board*: Abbott Laboratories Inc; AcuFocus, Inc; Alcon; Allergan; AqueSys, Inc; Bausch & Lomb Incorporated; Beaver-Visitec International; Carl Zeiss Meditec, Inc; ELENZA, Inc; Glaukos Corporation; Icon Bioscience; Kala Pharmaceuticals; Katena Products, Inc; LacriScience, LLC; Mati Therapeutics, Inc; Merck & Co, Inc; Mimetogen Pharmaceuticals; NovaBay Pharmaceuticals, Inc; Novaliq GmbH Germany; OcuHub LLC; Omeros Corporation; Pfizer Inc; PRN Pharmaceutical Research Network, LLC; ReSearch Pharmaceutical Services, Inc; Shire; StrathSpey Crown; TearLab Corporation; TLC Laser Eye Centers; TrueVision; and Versant Venture Management, LLC; *Ownership Interest*: AcuFocus, Inc; AqueSys, Inc; ELENZA, Inc; Glaukos Corporation; LacriScience, LLC; Mati Therapeutics, Inc; Mimetogen Pharmaceuticals; NovaBay Pharmaceuticals, Inc; OcuHub LLC; ReSearch Pharmaceutical Services, Inc; SARcode Bioscience, Inc; StrathSpey Crown; TearLab Corporation; TrueVision; and Versant Venture Management LLC.

Bonnie An Henderson, MD, had a financial agreement or affiliation during the past year with the following commercial interests in the form of *Consultant/Advisory Board*: Abbott Laboratories Inc; Alcon; Bausch & Lomb Incorporated; ClarVista Medical, Inc; Regeneron Pharmaceuticals, Inc; and Stealth BioTherapeutics Inc.

Edward J. Holland, MD, had a financial agreement or affiliation during the past year with the following commercial interests in the form of *Consultant/Advisory Board*: Alcon; Bausch & Lomb Incorporated; Kala Pharmaceuticals; Mati Therapeutics, Inc; PRN Pharmaceutical Research Network, LLC; ReSearch Pharmaceutical Services, Inc; Senju Pharmaceutical Co, Ltd; TearLab Corporation; and TearScience; *Contracted Research*: Alcon; Mati Therapeutics Inc; PRN Pharmaceutical Research Network, LLC; and Senju Pharmaceutical Co, Ltd; *Honoraria from promotional, advertising or non-CME services received directly from commercial interests or their Agents (eg, Speakers Bureaus)*: Alcon; Bausch & Lomb Incorporated; Omeros Corporation; Senju Pharmaceutical Co, Ltd; and TearScience; *Other/Travel Support*: Alcon; and Bausch & Lomb Incorporated.

Terry Kim, MD, had a financial agreement or affiliation during the past year with the following commercial interests in the form of *Consultant/Advisory Board*: Actavis/Allergan; Acuity Advisors LLC; Alcon; Bausch & Lomb Incorporated; CoDa Therapeutics, Inc; Foresight Biotherapeutics, Inc; Kala Pharmaceuticals; NovaBay Pharmaceuticals, Inc; Ocular Systems; Ocular Therapeutix, Inc; Oculeve Inc; Omeros Corporation; PowerVision, Inc; Presbyopia Therapies, LLC; Shire; Stealth BioTherapeutics Inc; TearLab Corporation; TearScience; and Valeant; *Honoraria from promotional, advertising or non-CME services received directly from commercial interests or their Agents (eg, Speakers Bureaus)*: Alcon; Bausch & Lomb Incorporated; Omeros Corporation; and Valeant; *Ownership Interest*: Ocular Therapeutix, Inc; and Omeros Corporation.

New York Eye and Ear Infirmary of Mount Sinai Peer Review Disclosure

Priti Batta, MD, has no relevant commercial relationships to disclose.



Editorial Support Disclosures

Cheryl Guttman Krader; Cynthia Tornallyay, RD, MBA, CHCP; Diane McArdle, PhD; Kimberly Corbin, CHCP; Barbara Aibel; and Michelle Ong have no relevant commercial relationships to disclose.

Disclosure Attestation

The contributing physicians listed above have attested to the following:

- 1) that the relationships/affiliations noted will not bias or otherwise influence their involvement in this activity;
- 2) that practice recommendations given relevant to the companies with whom they have relationships/affiliations will be supported by the best available evidence or, absent evidence, will be consistent with generally accepted medical practice; and
- 3) that all reasonable clinical alternatives will be discussed when making practice recommendations.

Off-Label Discussion

This educational activity might contain discussion of evidence-based and/or investigational uses of agents that are not indicated by the FDA. For additional information about approved uses, including approved indications, contraindications, and warnings, please refer to the official prescribing information for each product for discussion of approved indications, contraindications, and warnings.

For Digital Editions

System Requirements:

If you are viewing this activity online, please ensure the computer you are using meets the following requirements:

- **Operating System:** Windows or Macintosh
- **Media Viewing Requirements:** Flash Player or Adobe Reader
- **Supported Browsers:** Microsoft Internet Explorer, Firefox, Google Chrome, Safari, and Opera
- **A good Internet connection**

New York Eye and Ear Infirmary of Mount Sinai Privacy & Confidentiality Policies

<http://www.nyee.edu/health-professionals/cme/enduring-activities>

CME Provider Contact Information

For questions about this activity, call 212-979-4383.


To Obtain AMA PRA Category 1 Credit™

To obtain AMA PRA Category 1 Credit™ for this activity, read the material in its entirety and consult referenced sources as necessary. Complete the evaluation form along with the post test answer box within this supplement. Remove the Activity Evaluation/Credit Request page from the printed supplement or print the Activity Evaluation/Credit Request page from the Digital Edition. Return via mail to Kim Corbin, Director, ICME, New York Eye and Ear Infirmary of Mount Sinai, 310 East 14th Street, New York, NY 10003 or fax to (212) 353-5703. Your certificate will be mailed to the address you provide on the Activity Evaluation/Credit Request form. Please allow 3 weeks for Activity Evaluation/Credit Request forms to be processed. There are no fees for participating in and receiving CME credit for this activity.

Alternatively, we offer instant certificate processing and support Green CME. Please take this post test and evaluation online by going to <http://tinyurl.com/miosiscme>. Upon passing, you will receive your certificate immediately. You must score 70% or higher to receive credit for this activity, and may take the test up to 2 times. Upon registering and successfully completing the post test, your certificate will be made available online and you can print it or file it.

Disclaimer

The views and opinions expressed in this educational activity are those of the faculty and do not necessarily represent the views of New York Eye and Ear Infirmary of Mount Sinai, MedEdu LLC, Omeros Corporation, EyeNet, or American Academy of Ophthalmology.

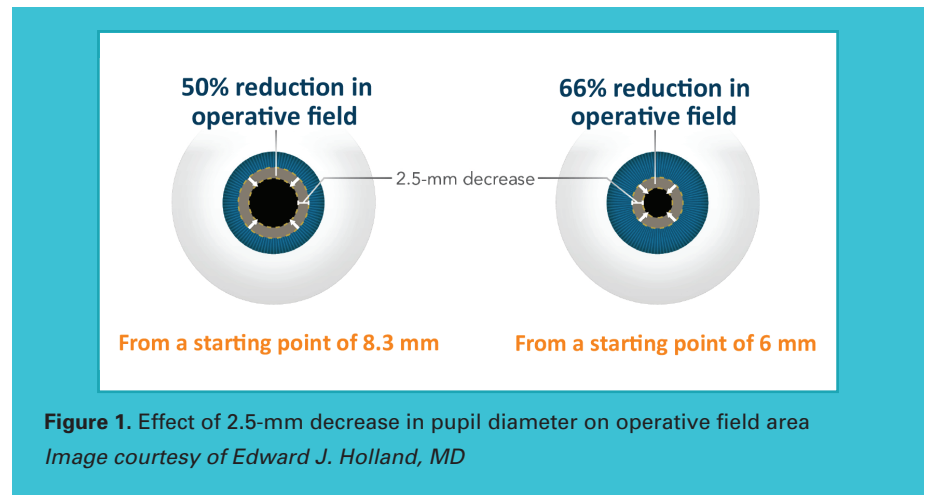


Case Discussions in Complicated Cataract Miosis Control and Other Surgical Pearls

The Significance of Miosis, Pain, and Inflammation in Cataract Surgery

Edward J. Holland, MD

Despite the advances occurring in cataract surgery over the past 4 decades, pupil size remains a critical determinant of surgical success. A small pupil limits intraocular visualization and the area of the operative field (Figure 1). As a result, a small pupil increases the difficulty of performing multiple steps in cataract surgery and the risk of complications. Capsulorhexis, phacoemulsification, cortical cleanup, intraocular lens (IOL) implantation, and, in the case of a toric IOL, IOL positioning, are all more challenging when the pupil is small, and corneal endothelial trauma, posterior capsule rupture, lens fragment retention, incomplete cortex removal, and vitreous loss are more likely to occur.¹⁻³ Operating through a small pupil also increases the chance of inadvertent iris touch during surgery, which will cause patient discomfort and pupil constriction, risks iris damage, and leads to increased postoperative inflammation and pain.



Significant pain after cataract surgery, whether it is associated with operating through a small pupil or not, can be alarming for patients and may be more common than surgeons realize. According to the findings of a systematic review of data from 21 published articles, up to 35% of patients reported moderate-to-severe pain in the early postoperative period after cataract surgery.⁴

The adverse outcomes associated with operating through a small pupil and the potential negative impact of surgery-related pain and inflammation on patient perceptions of the overall surgical experience and postoperative recovery need to be considered against the fact that today's cataract surgery population has high expectations for a comfortable procedure and an uneventful postoperative course with rapid vision rehabilitation.



At the same time, because lifespan is increasing, surgeons are operating on growing numbers of individuals who are older in age and more likely to have comorbidities associated with limited pupil dilation and/or risk for intraoperative miosis (Table 1).

Table 1. Risk Factors for Small Pupils/Intraoperative Miosis⁵⁻⁸

Intraoperative floppy iris syndrome/history of α 1-antagonist use

Dense brunescent cataract

Posterior synechiae

Pseudoexfoliation

Diabetes mellitus

History of intraocular surgery, trauma, or uveitis

Femtosecond laser-assisted cataract surgery

One of the most common clinical features associated with intraoperative miosis is a history of treatment with an α 1-antagonist. Medications in this class, which include tamsulosin, terazosin, doxazosin, alfuzosin, and silodosin, are being used by growing numbers of men for the treatment of urinary symptoms associated with benign prostatic hyperplasia (BPH), by women for urinary voiding problems, and as antihypertensive treatment.⁵ In addition, α -adrenergic receptor blockade is a feature of the herbal agent saw palmetto, finasteride, and some antipsychotic medications.

Systemic treatment with an α 1-antagonist blocks adrenergic stimulation of the pupillary dilator muscle and can lead to disuse atrophy with more chronic treatment.⁹ As a result, patients can develop intraoperative floppy iris syndrome (IFIS), a condition characterized by a flaccid iris that billows during normal fluid currents, a tendency for iris prolapse despite proper wound construction, and progressive intraoperative miosis. IFIS has been associated most often with tamsulosin, which is thought to reflect tamsulosin's selectivity for the α 1A-adrenoreceptor that is most prominent in the pupillary dilator muscle. IFIS, however, also occurs unexpectedly in patients without any history of α 1-antagonist use.

Dense brunescent cataract is another clinical feature associated with a higher rate of intraoperative miosis, perhaps reflecting the extended operative time of these cases.⁶ Other risk factors for intraoperative miosis include posterior synechiae; pseudoexfoliation (PXF); diabetes mellitus; a history of intraocular surgery, trauma, or uveitis; and femtosecond laser-assisted cataract surgery (FLACS).^{6,7}

It is clearly preferable to minimize inflammation and patient discomfort and avoid intraoperative miosis than to face the need to manage these issues. A variety of strategies exists for achieving these goals. The following series of case-based discussions will review their efficacy, safety, advantages, and limitations.

Inflammation and Pain Control: A Case of Cataract Surgery With a History of Iritis

—● Bonnie An Henderson, MD

Although modern cataract surgery is considered relatively atraumatic, any surgical trauma triggers an inflammatory response (Figure 2).¹⁰ The cascade of events begins with activation of phospholipase A2, which leads to the release of arachidonic acid. Arachidonic acid is converted by cyclooxygenase (COX)-1 and COX-2 into an intermediary that is subsequently metabolized by synthase enzymes into eicosanoids, including thromboxane A2 and several different prostaglandins.

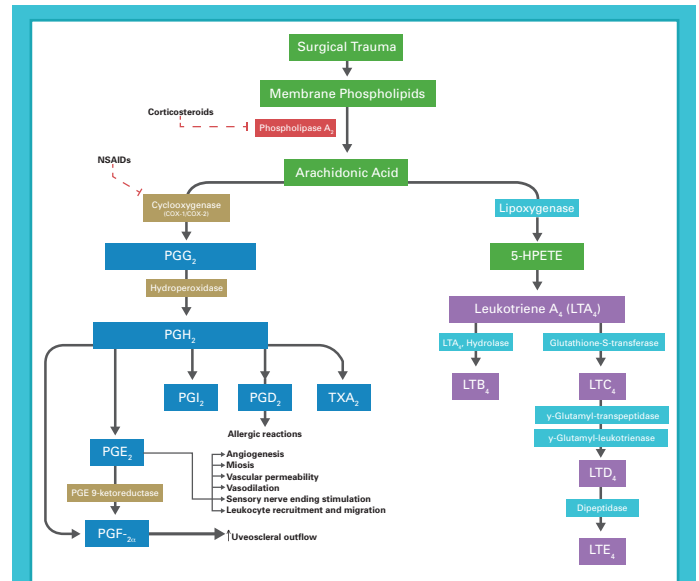


Figure 2. Inflammatory cascade induced as a result of surgical trauma

Abbreviation: NSAID, nonsteroidal anti-inflammatory drug.

Adapted from Kim SJ, et al.¹⁰

When released during cataract surgery, prostaglandins stimulate the iris sphincter muscle and sensory nerve endings, induce leukocyte recruitment and migration, and cause vascular dilation and permeability. These effects manifest intraoperatively as miosis and pain and postoperatively with the appearance of ocular redness, edema, pain, and anterior chamber cells and flare. Prostaglandins have also been implicated in the development of cystoid macular edema after cataract surgery.¹¹ Therefore, inhibiting prostaglandin biosynthesis using topical corticosteroids that block phospholipase A2 and/or topical nonsteroidal anti-inflammatory drugs (NSAIDs) that block the COX enzymes is a rational strategy for preventing intraoperative miosis and limiting postoperative inflammation and pain.



Case Illustration

A 59-year-old woman presents with a visually significant cataract OD. She has a history of recurrent iritis OU, with the last episode occurring over 1 year ago. On examination of her right eye, she has a quiet anterior chamber with posterior synechiae and an N03NC3 (LOCS [Lens Opacities Classification System] III) cataract. Best corrected visual acuity is 20/80, and intraocular pressure is 14 mm Hg.

This patient is at an increased risk for intraoperative miosis because of the presence of posterior synechiae.⁶ Synechiolysis should be performed to optimize mydriasis, and injection of an ophthalmic viscosurgical device (OVD) can be an effective technique to break the adhesions from the anterior capsule. Chondroitin sulfate-containing dispersive OVDs are particularly useful for this maneuver because of their superior retention in the eye compared with cohesive compounds.¹²

Anticipating the potential for the pupil to constrict with subsequent reduction of intraoperative visualization, it is also helpful in a case such as this to create a relatively large capsulotomy that will provide a greater margin of safety against inadvertently contacting the capsule with the phacoemulsification tip or chopper/lens manipulator.

Control of surgically induced inflammation is also important for this patient to minimize her risk for iritis recurrence. Uveitis specialists may even advocate use of oral and/or intravenous corticosteroids to suppress inflammation in patients with a history of an ocular inflammatory condition.¹³

Mechanical Pupil Management: A Case of IFIS and PXF

Eric D. Donnenfeld, MD

A number of mechanical devices can be used safely and effectively for expanding and maintaining dilation of a small pupil. Nevertheless, these modalities also suffer from a number of limitations; ideally, their use can be avoided through the application of some general principles for small pupil management and prevention of intraoperative miosis. In addition to pharmacologic pupil management (see next section), a mechanical instrument can be used for stretching the pupil as needed; however, this technique should be avoided in IFIS cases, in which it is not only ineffective, but may worsen miosis and iris prolapse.⁵

An OVD can also be used to help open the pupil and maintain dilation intraoperatively, and it will simultaneously serve as a tamponade to stop bleeding. OVDs that can be used for viscosydrisis include the highly cohesive viscoadaptive agent, sodium hyaluronate, 2.3%, which also reduces the risk of iris prolapse because of its high viscosity. Alternatively, dispersive materials, eg, sodium hyaluronate, 3.0%, and chondroitin sulfate, 4.0%, or sodium hyaluronate, 3.0%, can be used alone or in combination with a cohesive OVD in the soft-shell technique.

When using an OVD for pupil dilation, surgeons should direct the cannula at the edge of the pupil and then begin injecting the material while moving the cannula tip around the pupillary margin. Phacoemulsification should be performed using low aspiration flow and low vacuum settings to minimize OVD evacuation from the anterior chamber. Nevertheless, the benefit of viscosydrisis may be transient due to washout of the material, making repeat injections necessary.

When the preceding methods are ineffective in achieving the desired pupil size, if there is significant concern about intraoperative miosis, or if the pupil constricts during the procedure, surgeons can insert a pupillary expansion device that will remain in the eye during the procedure. Iris hooks are one option. Available in both reusable (4-0 polypropylene) and disposable (6-0 nylon) models, iris hooks are typically used in sets of 4 or 5 to create a diamond-shaped pupil. Each hook is placed through a separate limbal paracentesis and engaged around the iris margin (**Figure 3**). Careful arrangement of the hooks will optimize visualization and avoid interference with surgical instruments and maneuvers. In general, the hooks should not be placed adjacent to the cataract incision.

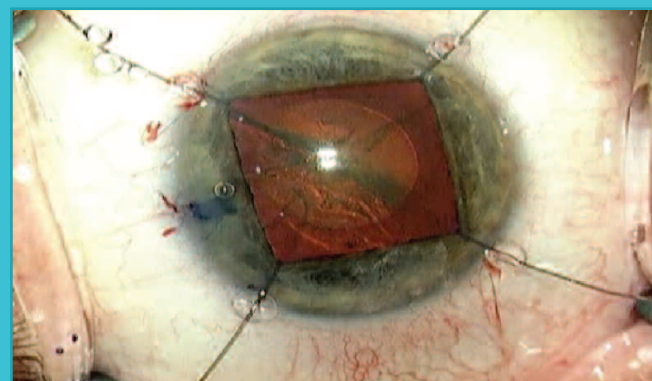


Figure 3. Four-point fixation with iris hooks
Image courtesy of Steven Shafron, MD

Iris hooks have the advantage of allowing surgeons to enlarge the pupil to a desired diameter. However, they may be best reserved for cases with an irregular iris/asymmetric pupil, considering that the focal application of pressure with iris hooks often leads to tearing of the iris sphincter, iris damage, and an irregular, tonic pupil. The need to make additional incisions is also a drawback of using iris hooks.

A pupil expansion ring is preferred over iris hooks in eyes with a round pupil because the pressure is distributed symmetrically over the points of contact with the iris. This reduces the risk of damaging the iris sphincter. Examples include a grooved, incomplete plastic ring that must be threaded along the pupillary margin using a metal injector (Perfect Pupil, Milvella, Savage, MN) (**Figure 4**); a silicone incomplete ring that is placed with an injector but requires bimanual expansion of the proximal segment (Graether 2000 Pupil Expander, EagleVision, Memphis, TN) (**Figure 5**); a foldable 5-0 polypropylene diamond-shaped device that is



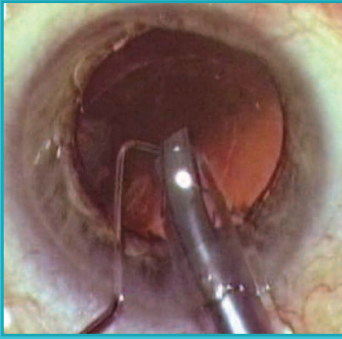


Figure 4. Perfect Pupil provides effective pupil dilation

Image courtesy of Eric D. Donnenfeld, MD




Figure 5. Graether 2000 Pupil Expander with fenestrated tab

Image courtesy of Eric D. Donnenfeld, MD

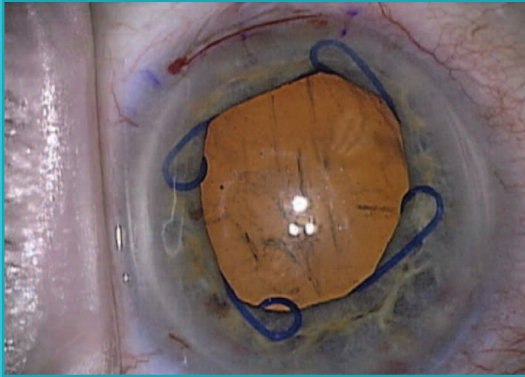


Figure 6. Eight-point fixation with a Malyugin Ring

Image courtesy of Eric D. Donnenfeld, MD

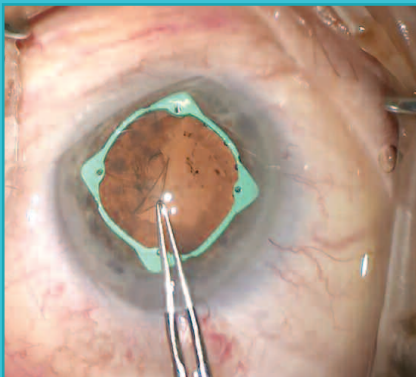


Figure 7. Fully engaged, the I-Ring provides continuous fixation and pupil dilation

Image provided to Eric D. Donnenfeld, MD, by Beaver-Visitec International

placed and removed with a disposable injector (Malyugin Ring, MicroSurgical Technology, Redmond, WA) (**Figure 6**); and a polyurethane circular device that is packaged with dedicated injector and extractor instruments (I-Ring, Beaver-Visitec International, Waltham, MA) (**Figure 7**).

The polypropylene ring is available in 2 sizes (6.25 mm and 7.00 mm) and engages the pupil with 4 circular scrolls located at each corner to effectively give an 8-point fixation. The polyurethane device provides 360° pupillary support and therefore is very effective in maintaining a stable area of surgical exposure while minimizing the risk for postoperative pupil distortion.

Compared with incomplete rings, the diamond-shaped and circular devices are easier to insert and remove, although surgeons must take care when removing the devices to avoid causing iris disinsertion and bleeding. Anecdotally, based on limited early clinical experience, pigment release may be less likely when using the I-Ring.

As a major advantage, pupillary expansion rings are predictably effective for expanding and maintaining a stable pupil diameter. Although placement of any of the pupillary expansion devices can be more difficult in eyes with a shallow anterior chamber, surgeons can overcome that challenge by performing dry, sutureless pars plana vitrectomy using 25-gauge instrumentation.

However, use of any of the pupillary expansion rings adds time and risk because of the potential to cause iris trauma, which can lead to bleeding, pain, inflammation, and iris sphincter damage. Cost is another drawback associated with their use. Although procedures requiring a mechanical pupil expansion device qualify as complex cataract surgery and therefore result in a higher reimbursement for the surgeon, there is no additional facility fee for ambulatory surgery centers or hospital outpatient departments.

Case Illustration

A 66-year-old man presents with a visually significant cataract and PXF. He has BPH, for which he is being treated with an $\alpha 1$ -antagonist. His pupil diameter at maximum dilation is 4.5 mm.

Given this patient's small pupil, despite maximal preoperative topical dilating drops, and the presence of risk factors for intraoperative miosis, a 5-0 polypropylene pupil expansion device (I-Ring) was placed after injecting OVD to lift the iris and enable engagement of the pupillary margin. Dimpling of the capsule with injection of OVD during the procedure indicated the PXF was associated with significant loss of zonular integrity, and a capsular tension ring was also inserted. With the benefit of the pupil expansion device and insertion of a capsular tension ring, the case was completed uneventfully. Postoperative rehabilitation was rapid, with return of excellent uncorrected visual acuity.

Pharmacologic Pupil Management: A Case of Intraoperative Miosis With FLACS

• Terry Kim, MD

Intraoperative miosis poses big challenges for cataract surgeons and increases the risk for complications. Common causes of a small pupil/intraoperative miosis have included aging, chronic miotic use, diabetes, Horner syndrome, IFIS, PXF, and synechiae.^{6,7} Now, with increasing use of FLACS, a new cause for intraoperative miosis has emerged.^{8,14} This problem has been reported to occur in approximately one-fourth to one-third of cases relying on a preoperative dilating regimen with tropicamide alone or combined with phenylephrine. It may become most problematic, however, in challenging cases, in which some surgeons are preferentially using the laser by virtue of the longer operating time in those eyes.

In addition to the usual problems accompanying intraoperative miosis, reduced visualization in FLACS can make certain portions of the cataract procedure more difficult for surgeons, such as subincisional cortex removal, a step that is already more challenging in FLACS cases than in conventional cataract surgery.

When confronting a case at risk for a small pupil/intraoperative miosis, it is helpful for surgeons to consider the mechanism, which may guide the preventive strategy (Table 2). FLACS-related intraoperative miosis is mediated by prostaglandins that are released when the femtosecond laser cuts into the anterior capsule,¹⁵ and so there is a rationale for using a pharmacologic regimen that incorporates an NSAID to mitigate prostaglandin synthesis.^{8,14}

Table 2. Causes and Mechanisms of Small Pupils

Etiology	Mechanism
Aging	Atrophy of iris
Chronic miotic use	Fibrosis of iris sphincter
Diabetes	Autonomic dysfunction or rubeosis
Horner syndrome	Sympathetic denervation
IFIS	Atrophic dilator muscle from chronic α 1A-adrenoreceptor blockade
PXF	Atrophic iris dilator muscle vs fibrosis of sphincter muscle
Synechiae	Uveitis, trauma, angle closure, or prior surgery
FLACS	Prostaglandin release

Table courtesy of Terry Kim, MD

Topical medications are the standard for pupil dilation in cataract surgery, and they are relatively inexpensive.³ The medications used include antimuscarinic drugs that relax the pupillary sphincter muscle (eg, cyclopentolate and tropicamide), sympathomimetic/adrenergic agents that stimulate the pupillary dilator muscle (eg, phenylephrine), and NSAIDs that block prostaglandin-mediated reflex miosis.^{3,16} Flurbiprofen is the only topical NSAID available in the United States that is approved for inhibiting intraoperative miosis.¹⁶ Other NSAIDs have also been shown to have a mydriatic effect.¹⁰ In a randomized study, topical ketorolac, 0.5%, produced more stable mydriasis throughout surgery compared with flurbiprofen.¹⁷

Topical mydriatic regimens, however, may be unpredictably effective for maintaining mydriasis because of washout from the anterior chamber during surgery.¹⁸⁻²¹ In a study of patients who began treatment with topical ketorolac on the day before cataract surgery, levels of the NSAID in aqueous humor samples drawn at the end of the procedure were consistently nominal or below the level of detection.¹⁸ Other limitations of topical mydriatic medications include the need for intensive preoperative dosing by the nursing staff and the potential for causing systemic side effects as a result of absorption through the conjunctiva and nasal mucosa.²¹

Mydriatic agents may also be administered as single agents or combinations directly into the anterior chamber, either as an injection or through infusion after addition of the medication to the bottle of irrigation solution.^{3,20} Historically, medications used via the intracameral route for mydriasis during cataract surgery include epinephrine, phenylephrine, cyclopentolate, and lidocaine.^{3,19}

Intracameral administration of these mydriatic agents, like a topical regimen, is inexpensive, but has the advantages of reducing nursing time and the risk of systemic adverse events.³ The intracameral approach also provides a more rapid onset and sustained efficacy relative to topical administration, particularly when the medication is added to the infusion bottle and delivered throughout the procedure. However, drawbacks with intracameral administration of these medications as mydriatic agents should be considered. With the exceptions of preservative-free/bisulfite-free epinephrine and preservative-free/sulfite-containing epinephrine when diluted in ophthalmic irrigation fluid, their use is off label.^{22,23} Compounding using these or other medications introduces the potential for dosing errors and contamination. In fact, because of safety concerns, some surgical facilities are prohibiting intraocular use of any medications that are compounded in the operating room, and licensing and regulatory agencies are increasingly scrutinizing these off-label practices. In addition, use of products containing preservatives can cause toxic anterior shock syndrome,²⁴ and exposure to undiluted products containing bisulfite can cause corneal endothelial toxicity.²⁵

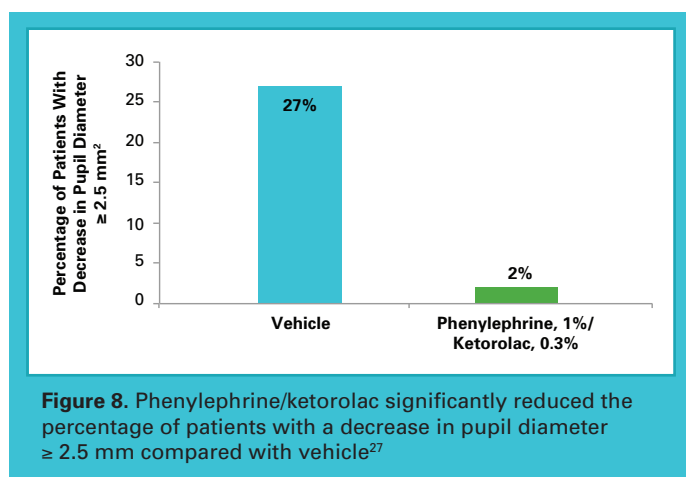
A commercially available fixed combination of phenylephrine, 1%/ketorolac, 0.3% (phenylephrine/ketorolac), added to a 500-mL irrigation solution bottle offers a new intracameral option for preventing intraoperative miosis.²⁶ This product is a clear, colorless, sterile, preservative-free, and bisulfite-free solution that comes packaged in single



patient-use vials. It is approved by the FDA for maintaining pupil size during cataract surgery or IOL replacement and for reducing postoperative ocular pain.²⁶ Use of phenylephrine/ketorolac injection avoids the potential for human error and other problems associated with compounding medications. There is no added cost for the surgeon or surgical facility to use the phenylephrine/ketorolac solution, and the cost of the agent is covered by Medicare and other third-party payers when it is used for its FDA-approved indication. Phenylephrine/ketorolac also qualifies for pass-through payment under the Outpatient Prospective Payment System.

Blood pressure elevation due to systemic phenylephrine exposure is the primary safety concern with this modality. In an integrated analysis of safety data from 2 phase 3 placebo-controlled clinical trials investigating the phenylephrine/ketorolac injection, no differences between treatment groups in serial assessments of vital signs were reported.²⁷ In addition, the incidence of treatment-emergent adverse events was higher in the control group receiving placebo than in patients receiving the phenylephrine/ketorolac injection (66.9% vs 60%), and all severe treatment-emergent adverse events considered to be related to study treatment occurred in patients receiving placebo.

Several premarketing clinical trials demonstrated the efficacy of phenylephrine/ketorolac for maintaining pupil size during cataract surgery and controlling postoperative pain.^{20,27} Analyses of the pooled data from the 2 phase 3 studies showed phenylephrine/ketorolac met its coprimary outcome measures, achieving significant differences compared with placebo in the mean area under the curve (AUC) change from baseline in pupil diameter (0.08 vs -0.50 mm; $P < .0001$) and in mean AUC of ocular pain visual analog scale scores within 12 hours postoperatively (4.16 mm vs 9.06 mm; $P < .001$).²⁷ Phenylephrine/ketorolac also achieved superiority over placebo in key secondary efficacy analyses that assessed the percentage of patients with a pupil diameter < 6.0 mm at cortical cleanup; pupil diameter < 6.5 mm at any time during surgery; ≥ 2.5 mm of pupillary constriction at any time during surgery (**Figure 8**); no pain at all time points after surgery; moderate-to-severe pain at any time point; and analgesic use on the day of surgery ($P \leq .0027$ for all comparisons).



To supplement the benefits of using a phenylephrine/ketorolac injection in the irrigation solution, some surgeons are withdrawing aliquots of the mixed solution to use as an initial intracameral injection through the paracentesis and then later in the case for hydrodissection and stromal hydration. Anecdotally, this direct intracameral injection of an irrigation solution containing the phenylephrine/ketorolac injection seems to cause less burning and stinging compared with intracameral injection of epi-Shugarcaine (bisulfite-free epinephrine and preservative-free lidocaine mixed into an irrigation solution).

Most importantly, when encountering intraoperative miosis with FLACS, my experience has shown the benefits of using an FDA-approved agent of phenylephrine and ketorolac throughout the procedure, which can help increase and maintain pupil size to facilitate visualization during phacoemulsification, cortex removal, and IOL implantation, with the ultimate goal of preventing intraoperative complications and improving postoperative outcomes.

Case Illustration

A 62-year-old man with bilateral cataracts and ~2.5 D of regular astigmatism in both eyes is interested in reduced spectacle dependence for activities involving distance vision. He chooses toric IOLs and elects to undergo FLACS for both eyes.

Surgery is performed first on his dominant eye, which dilates to 8.0 mm with preoperative drops. However, following the femtosecond laser portion of the surgery, the pupil is noted to decrease in size. At the start of the surgery, he receives an intracameral injection of epi-Shugarcaine. The pupil stays well dilated during nucleus and epinucleus removal, but then begins to come down again so that the edge of the capsulotomy is no longer visible. A polypropylene pupil expansion ring is inserted to enable complete cortex removal, along with implantation and alignment of the toric IOL.

Two weeks later, surgery is performed on his second eye, which also dilates to 8.0 mm with preoperative drops. Once again, the pupil size is noted to decrease in size following femtosecond laser application. Phenylephrine/ketorolac injection is added to the irrigation solution bottle for this surgery and is also used for intracameral injection through the paracentesis incision prior to initiating phacoemulsification to address the small pupil. The pupil stays well dilated throughout the entire case, particularly during cortex removal and toric IOL implantation and alignment, and eliminates the need for a pupil expansion device.



Other Surgical Pearls for Addressing Cataract Surgery Complications

Complicated cataract surgery comprises a myriad of situations in addition to intraoperative miosis. In the following, faculty members offer pearls for addressing selected challenges.

FLACS for the Mature White Cataract

—● Terry Kim, MD

Capsulorhexis is the most difficult step in cases involving a mature white cataract because of the lack of red reflex and the presence of elevated intracapsular pressure that can cause an uncontrollable radial tear, the so-called Argentinian flag sign. One strategy for increasing the safety of capsulorhexis is to first decompress the capsular bag by puncturing the anterior capsule with a 25-gauge needle and aspirating out the liquefied cortex.

Use of the femtosecond laser for capsulotomy represents an alternative approach. The laser system is able to identify the anterior capsule and create a complete capsulotomy (Figure 9) within a closed system, thereby reducing the chance of a radial tear in the anterior capsule.

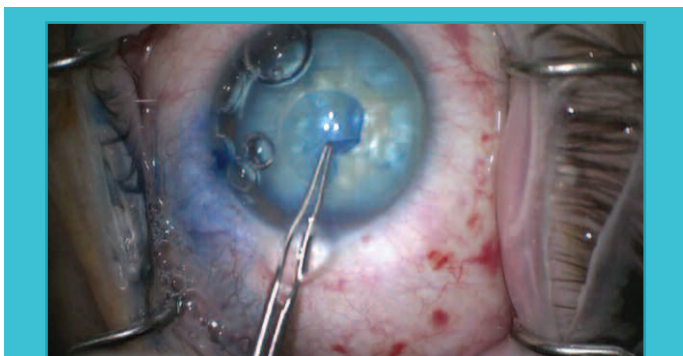


Figure 9. Trypan blue staining shows the femtosecond laser created a complete capsulotomy in this eye with a mature white cataract

Image courtesy of Terry Kim, MD

Loose Zonules

—● Bonnie An Henderson, MD

Loose zonules present multiple challenges for cataract surgery. Although loss of zonular integrity may be recognized or suspected preoperatively based on findings of the clinical examination or history, it is not unusual that this problem will only be recognized during surgery. Posterior displacement of the entire lens and capsular bag complex when applying force to the nucleus with the phaco tip during chopping is one intraoperative sign of loose zonules.

Once the problem is appreciated, surgeons should maintain the phaco tip in the eye and inject additional viscoelastic to keep the anterior chamber formed. Then, iris or capsular hooks can be used to stabilize the capsule. Considering the

likelihood of encountering loose zonules in eyes with PXF, iris hooks may be considered the preferred option over other methods, such as rings, for managing a small pupil in eyes with PXF, where they can then be used for capsular bag support, if needed.

Scleral Fixation With the Glued IOL Technique

—● Eric D. Donnenfeld, MD

The glued IOL technique introduced by Amar Agarwal, MD, has become my preferred method for managing a dislocated 3-piece IOL with polypropylene haptics.²⁸ It effectively secures the IOL in a stable position and avoids lens exchange, suturing, and suturing-related complications, and the polypropylene haptics will not degrade over time.

Briefly, the technique involves the creation of 2 scleral flaps 180° apart, 2 sclerotomies under each flap, through which the haptics are externalized, and 2 scleral incisions, into which the haptics are tucked and glued. Pars plana vitrectomy is performed to avoid retinal traction during IOL manipulation, and then the IOL is brought into the anterior chamber by grabbing one haptic in a tire-iron technique and pushing the optic from behind with forceps. Any cortex present in the capsular bag can be removed using the vitrectomy probe in IA mode.

In series, the haptics are manipulated through the sclera using a handshake technique to transfer the haptic from one hand to the other. One microforceps holds the haptic in the anterior chamber and passes the haptic to a microforceps passed through the sclerotomy in the posterior chamber. The haptic is then externalized through the scleral incision under the flap (Figure 10). Once the haptic is placed into the scleral pocket, fibrin glue is used to seal the scleral flaps and conjunctiva. I also inject triamcinolone into the vitreous humor through the pars plana incision to reduce inflammation, and in my experience, these eyes are very quiet the next day.

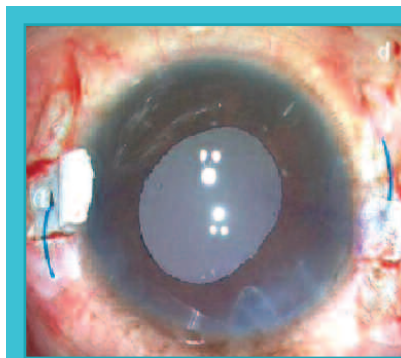


Figure 10. Haptics visualized under scleral flaps prior to placement into scleral incision

Image courtesy of Eric D. Donnenfeld, MD

Go to next page for **Key Learning Points** ►



Key Learning Points

Intraoperative miosis creates challenges in cataract surgery, affecting:

- Visualization and surgical field
- Capsulorhexis, phacoemulsification, cortical cleanup, IOL implantation, and alignment
- Risk for complications and postoperative pain, inflammation, and patient satisfaction

Chances of encountering intraoperative miosis are increased by:

- Comorbidities present in an aging cataract surgery population
- FLACS

Prevention is the best management for intraoperative miosis

- Traditional options (eg, topical drops, viscomydriasis, mechanical approaches, and off-label intracameral injections/infusions) have limitations

Phenylephrine/ketorolac injection for preventing intraoperative miosis:

- Is FDA approved
- Simultaneously controls postoperative pain and inflammation
- Carries no cost to the surgeon or surgery center

Iris hooks for pupil management in eyes with PKF can double as capsular hooks if loose zonules are identified intraoperatively.

FLACS offers a new technique for safe capsulotomy creation in eyes with a mature white cataract.

The glued IOL technique is a simple, safe, and effective method for securing a dislocated posterior chamber IOL without sutures.

References

1. Guzek JP, Holm M, Cotter JB, et al. Risk factors for intraoperative complications in 1000 extracapsular cataract cases. *Ophthalmology*. 1987;94(5):461-466.
2. Narendran N, Jaycock P, Johnston RL, et al. The Cataract National Dataset electronic multicentre audit of 55,567 operations: risk stratification for posterior capsule rupture and vitreous loss. *Eye (Lond)*. 2009;23(1):31-37.
3. Behndig A, Korobelnik JF. Mydriatic insert and intracameral injections compared with mydriatic eyedrops in cataract surgery: controlled studies. *J Cataract Refract Surg*. 2015;41(7):1503-1519.
4. Porela-Tiihonen S, Kaarniranta K, Kokki H. Postoperative pain after cataract surgery. *J Cataract Refract Surg*. 2013;39(5):789-798.
5. Chang DF, Braga-Mele R, Mamalis N, et al; ASCRS Cataract Clinical Committee. ASCRS White Paper: clinical review of intraoperative floppy-iris syndrome. *J Cataract Refract Surg*. 2008;34(12):2153-2162.
6. American Academy of Ophthalmology Cataract and Anterior Segment Panel. *Preferred Practice Pattern®: Cataract in the Adult Eye*. San Francisco, CA: American Academy of Ophthalmology; 2011.
7. Megbelayin EO, Pindikura S. Managing challenges of recalcitrant intra-operative miosis during small incision cataract surgery. *Int J Scient Res Knowl*. 2013;1(5):74-81.
8. Yeoh R. Intraoperative miosis in femtosecond laser-assisted cataract surgery. *J Cataract Refract Surg*. 2014;40(5):852-853.
9. Chang DF, Campbell JR, Colin J, Schweitzer C; Study Surgeon Group. Prospective masked comparison of intraoperative floppy iris syndrome severity with tamsulosin versus alfuzosin. *Ophthalmology*. 2014;121(4):829-834.
10. Kim SJ, Flach AJ, Jampol LM. Nonsteroidal anti-inflammatory drugs in ophthalmology. *Surv Ophthalmol*. 2010;55(2):108-133.
11. Miyake K, Ibaraki N. Prostaglandins and cystoid macular edema. *Surv Ophthalmol*. 2002;47(suppl 1):S203-S218.
12. Petroll WM, Jafari M, Lane SS, Jester JV, Cavanagh HD. Quantitative assessment of ophthalmic viscosurgical device retention using in vivo confocal microscopy. *J Cataract Refract Surg*. 2005;31(12):2363-2368.
13. American Academy of Ophthalmology. *Preferred Practice Pattern® Clinical Questions: Uveitis and Cataract Surgery*. San Francisco, CA: American Academy of Ophthalmology; 2012.
14. Nagy ZZ, Takacs AI, Filkorn T, et al. Complications of femtosecond laser-assisted cataract surgery. *J Cataract Refract Surg*. 2014;40(1):20-28.
15. Schultz T, Joachim SC, Stellbogen M, Dick HB. Prostaglandin release during femtosecond laser-assisted cataract surgery: main inducer. *J Refract Surg*. 2015;31(2):78-81.
16. Ocufen [package insert]. Irvine, CA: Allergan; 2012.
17. Solomon KD, Turkalj JW, Whiteside SB, Stewart JA, Apple DJ. Topical 0.5% ketorolac vs 0.03% flurbiprofen for inhibition of miosis during cataract surgery. *Arch Ophthalmol*. 1997;115(9):1119-1122.
18. Katsev DA, Katsev CC, Pinnow JM. Intracameral ketorolac concentration after topical ketorolac administration prior to cataract surgery. Paper presented at: ASCRS-ASOA Symposium & Congress; April 17-21, 2015; San Diego, CA. Abstract 11161.
19. Lawuyi LE, Gurbaxani A. The clinical utility of new combination phenylephrine/ketorolac injection in cataract surgery. *Clin Ophthalmol*. 2015;9:1249-1254.
20. Lindstrom RL, Loden JC, Walters TR, et al. Intracameral phenylephrine and ketorolac injection (OMS302) for maintenance of intraoperative pupil diameter and reduction of postoperative pain in intraocular lens replacement with phacoemulsification. *Clin Ophthalmol*. 2014;8:1735-1744.
21. Grob SR, Gonzalez-Gonzalez LA, Daly MK. Management of mydriasis and pain in cataract and intraocular lens surgery: review of current medications and future directions. *Clin Ophthalmol*. 2014;8:1281-1289.
22. Epinephrine injection USP [package insert]. Largo, FL: Belcher Pharmaceuticals, LLC; 2015.
23. Adrenalin [package insert]. Rochester, MI: JHP Pharmaceuticals LLC; 2012.
24. Mamalis N, Edelhauser HF, Dawson DG, Chew J, LeBoyer RM, Werner L. Toxic anterior segment syndrome. *J Cataract Refract Surg*. 2006;32(2):324-333.
25. Slack JW, Edelhauser HF, Helenek MJ. A bisulfite-free intraocular epinephrine solution. *Am J Ophthalmol*. 1990;110(1):77-82.
26. Omidria [package insert]. Seattle, WA: Omeros Corporation; 2015.
27. Hovanesian JA, Sheppard JD, Trattler WB, et al. Intracameral phenylephrine and ketorolac during cataract surgery to maintain intraoperative mydriasis and reduce postoperative ocular pain: integrated results from 2 pivotal phase 3 studies. *J Cataract Refract Surg*. 2015;41(10):2060-2068.
28. Agarwal A, Kumar DA, Jacob S, Baid C, Agarwal A, Srinivasan S. Fibrin glue-assisted sutureless posterior chamber intraocular lens implantation in eyes with deficient posterior capsules. *J Cataract Refract Surg*. 2008;34(9):1433-1438.





CME Post Test Questions

To obtain *AMA PRA Category 1 Credit™* for this activity, complete the CME Post Test by writing the best answer to each question in the Answer Box located on the Activity Evaluation/Credit Request form on the following page. Alternatively, you can complete the CME Post Test online at <http://www.tinyurl.com/miosiscme>.

See detailed instructions under **To Obtain AMA PRA Category 1 Credit™** on page 3.

- When a 6-mm pupil constricts by 2.5 mm, what is the decrease in operative field area?
 - 18%
 - 33%
 - 50%
 - 66%
- As reported in a systematic review of 21 published articles, up to what percentage of patients reported moderate-to-severe pain immediately after cataract surgery?
 - 10%
 - 25%
 - 35%
 - 50%
- Which of the following is not a risk factor for intraoperative pupillary constriction during cataract surgery?
 - Diabetes mellitus
 - Oral aspirin use
 - Oral saw palmetto use
 - Use of femtosecond laser for capsulotomy and lens softening
- Which of the following pharmacologic mechanisms of action is not a rational strategy for limiting inflammation after cataract surgery?
 - Lipoxygenase inhibition
 - Phospholipase A2 inhibition
 - Cyclooxygenase inhibition
 - All of the above
- Viscomydriasis with an OVD:
 - Should be avoided in eyes at risk for IFIS due to increased risk of iris prolapse
 - Should be used in conjunction with low aspiration flow and low vacuum settings
 - Is only effective when using a dispersive product
 - Reliably maintains pupil dilation during surgery if the soft-shell technique is used
- Pupillary expansion rings:
 - Are preferred over iris hooks in eyes with a round pupil
 - Are contraindicated in eyes with a shallow anterior chamber due to the risk of corneal endothelial trauma
 - Avoid the risk of iris sphincter damage
 - Should be avoided in eyes with PXF due to concern about release of iris pigment and fibrillary deposits
- Intracameral administration of mydriatic agents:
 - Increases the risk of systemic adverse events relative to topical treatment
 - Is off-label use for all medications except phenylephrine, 1%/ketorolac, 0.3%
 - May result in endothelial toxicity using undiluted products containing bisulfites
 - Significantly increases time in the operating room to allow for a relatively slow onset of action
- Intraoperative miosis during FLACS:
 - Is mediated by acetylcholine release
 - Is mediated by prostaglandin release
 - Is prevented using a preoperative topical dilating regimen that includes both an antimuscarinic and an adrenergic agent
 - Makes FLACS contraindicated in patients if the preoperative pupil diameter is ≤ 6.0 mm
- According to its prescribing information, phenylephrine, 1%/ketorolac, 0.3%, injection is recommended for:
 - Injection directly into the anterior chamber without dilution
 - Injection through the zonules at the beginning of the case
 - Addition to the infusion bottle
 - Use only in cases in which there is poor pupillary dilation
- Phenylephrine, 1%/ketorolac, 0.3%, injection is approved for:
 - Maintaining pupil size during cataract surgery
 - Preoperative induction of miosis
 - Preventing postcataract surgery cystoid macular edema
 - Preventing inflammation after cataract surgery



Activity Evaluation/Credit Request

Original Release: April 1, 2016

Last Review: March 1, 2016

Expiration: April 30, 2017

Case Discussions in Complicated Cataract: Miosis Control and Other Surgical Pearls

Proceedings From a CME Symposium During AAO 2015

To receive *AMA PRA Category 1 Credit™*, you must complete this **Evaluation** form and the **Post Test**. Record your answers to the **Post Test** in the **Answer Box** located below. Mail or Fax this completed page to **New York Eye and Ear Infirmary of Mount Sinai–ICME**, 310 East 14th Street, New York, NY 10003 (Fax: 212-353-5703). Your comments help us to determine the extent to which this educational activity has met its stated objectives, assess future educational needs, and create timely and pertinent future activities. Please provide all the requested information below. This ensures that your certificate is filled out correctly and is mailed to the proper address. It also enables us to contact you about future CME activities. Please print clearly or type. Illegible submissions cannot be processed.

PARTICIPANT INFORMATION (Please Print) Home Office

Last Name _____ First Name _____
 Specialty _____ Degree MD DO OD PharmD RPh NP RN PA Other _____
 Institution _____
 Street Address _____
 City _____ State _____ ZIP Code _____ Country _____
 E-mail _____ Phone _____ Fax _____

Please note: We do not sell or share e-mail addresses. They are used strictly for conducting post-activity follow-up surveys to assess the impact of this educational activity on your practice.

Learner Disclosure: To ensure compliance with the US Centers for Medicare and Medicaid Services regarding gifts to physicians, **New York Eye and Ear Infirmary of Mount Sinai** Institute for CME requires that you disclose whether or not you have any financial, referral, and/or other relationship with our institution. **CME certificates cannot be awarded unless you answer this question.** For additional information, please call NYEE ICME at 212-979-4383. Thank you.

Yes No I and/or my family member have a financial relationship with **New York Eye and Ear Infirmary of Mount Sinai** and/or refer Medicare/Medicaid patients to it.

I certify that I have participated in the entire activity and claim 1.5 *AMA PRA Category 1 Credits™*.

Signature Required _____ Date Completed _____

OUTCOMES MEASUREMENT

Yes No Did you perceive any commercial bias in any part of this activity? **IMPORTANT! If you answered “Yes,” we urge you to be specific about where the bias occurred so we can address the perceived bias with the contributor and/or in the subject matter in future activities.**

Circle the number that best reflects your opinion on the degree to which the following learning objectives were met:
5 = Strongly Agree 4 = Agree 3 = Neutral 2 = Disagree 1 = Strongly Disagree

Upon completion of this activity, I am better able to:

• Identify optimal strategies for control of postoperative pain and inflammation for patients undergoing intraocular lens replacement	5	4	3	2	1
• Evaluate the benefits and risks of pharmacological agents for managing miosis	5	4	3	2	1
• Appraise the safety and efficacy of mechanical devices for managing miosis	5	4	3	2	1
• Incorporate evidence-based approaches for mydriasis maintenance in complicated cataract cases	5	4	3	2	1

1. Please list one or more things, if any, you learned from participating in this educational activity that you did not already know. _____

2. As a result of the knowledge gained in this educational activity, how likely are you to implement changes in your practice?
4 = definitely will implement changes 3 = likely will implement changes 2 = likely will not implement any changes 1 = definitely will not make any changes
 4 3 2 1

Please describe the change(s) you plan to make: _____

3. Related to what you learned in this activity, what barriers to implementing these changes or achieving better patient outcomes do you face? _____

4. Please check the Core Competencies (as defined by the Accreditation Council for Graduate Medical Education) that were enhanced for you through participation in this activity.

Patient Care Practice-Based Learning and Improvement Professionalism
 Medical Knowledge Interpersonal and Communication Skills Systems-Based Practice

5. What other topics would you like to see covered in future CME programs? _____

ADDITIONAL COMMENTS _____

POST TEST ANSWER BOX

1	2	3	4	5	6	7	8	9	10